

## THE CLINICAL PICTURE

FÁTIMA TOUS-ROMERO, MD

Department of Dermatology,  
Hospital 12 de Octubre, Madrid, Spain

SARA BURILLO-MARTÍNEZ, MD

Department of Dermatology,  
Hospital 12 de Octubre, Madrid, Spain

MARTA PRIETO-BARRIOS, MD

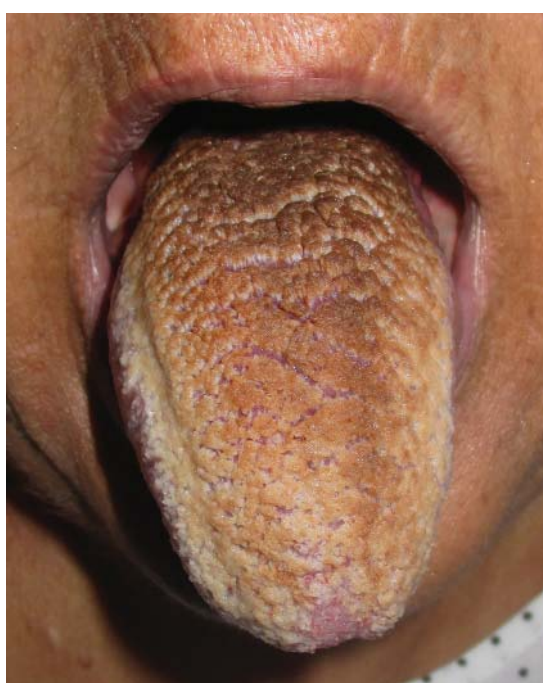Department of Dermatology,  
Hospital 12 de Octubre, Madrid, Spain

LIDIA MAROÑAS-JIMÉNEZ, MD

Department of Dermatology,  
Hospital 12 de Octubre, Madrid, Spain

# Black hairy tongue cured concurrently with respiratory infection

Proposed causes include medications, hyposalivation, poor oral hygiene, smoking, and infection

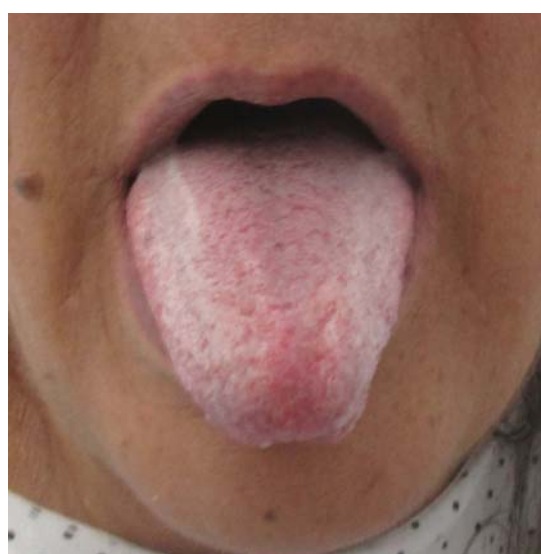


**FIGURE 1.** At presentation, lesions were spread across the dorsum of the tongue.

**A** 54-YEAR-OLD FEMALE smoker was admitted to the hospital for fever and respiratory infection. On the day of admission, she reported lesions of the oral mucosa for the past several months. She denied taking any medications recently.

Physical examination showed brownish papillary lesions spread across the dorsum of the tongue; the lesions were a darker shade proximally (**Figure 1**), leading to the diagnosis of black hairy tongue. Hygienic measures were recommended, with other treatment options to be considered later, if necessary. Of

doi:10.3949/ccjm.84a.16044



**FIGURE 2.** The condition had resolved 1 week later.

note, during her 1-week hospital stay, she was treated with levofloxacin for the respiratory infection, and she did not smoke during this period. One week after her admission, the lesions had disappeared (**Figure 2**).

### ■ LINGUA VILLOSA NIGRA

Black hairy tongue (lingua villosa nigra) is a rare but benign condition caused by defective desquamation and reactive hypertrophy of the filiform papillae of the tongue. Causes that have been proposed include medications, hyposalivation, poor oral hygiene, oxidizing mouthwashes (eg, hydrogen peroxide), alcohol, smoking, and infection.<sup>1</sup>

The differential diagnosis includes acanthosis nigricans, oral hairy leukoplakia, oral candidiasis, pigmented fungiform papillae, Ad-

dison disease, and black staining over a normal tongue from bismuth or food colorings.

### ■ DIAGNOSIS AND TREATMENT

Visual inspection and a detailed history are often sufficient for diagnosis. The optimal treatment is unclear, but the condition can improve with hygienic measures alone, topical or oral retinoids,<sup>2</sup> topical triamcinolone acetonide, salicylic acid, vitamin B complex, or antifungals. There are isolated cases in the literature in which improvement occurred with antibiotics, but their role is unclear.<sup>1</sup> Rarely, surgical excision of the filiform papilla in black hairy tongue has been done for symptomatic relief and cosmetic purposes.<sup>3</sup>

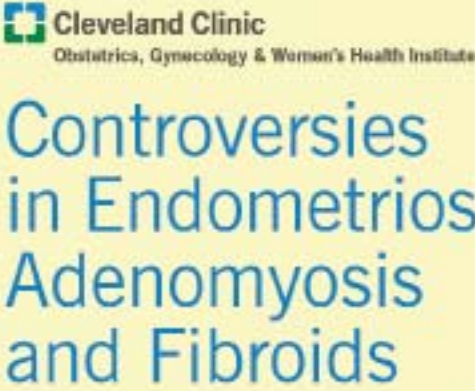
While our patient presented with typical features of black hairy tongue, which resolved

with hygienic measures and smoking cessation, we could not completely rule out the contribution of antibiotics given for the respiratory infection. It is important to keep this disease in mind to avoid unnecessary tests and to apply the most appropriate treatment according to the patient's symptoms. ■

### ■ REFERENCES

1. Nakajima M, Mizooka M, Tazuma S. Black hairy tongue treated with oral antibiotics: a case report. *J Am Geriatr Soc* 2015; 63:412–413.
2. Gurvits GE, Tan A. Black hairy tongue syndrome. *World J Gastroenterol* 2014; 20:10845–10850.
3. Stringer LL, Zitella L. Hyperpigmentation of the tongue. *J Adv Pract Oncol* 2014; 5:71–72.


ADDRESS: Fátima Tous-Romero, MD, Department of Dermatology, Hospital 12 de Octubre, Avda de Córdoba s/n, 28041 Madrid, Spain; Fatimatousro@gmail.com



**Cleveland Clinic**  
Obstetrics, Gynecology & Women's Health Institute

# Controversies in Endometriosis, Adenomyosis and Fibroids

**August 25 – 26, 2017**  
InterContinental Hotel and Bank of America  
Conference Center, Cleveland, OH



Discover the latest advances in the diagnosis and management of endometriosis, adenomyosis and fibroids. Learn from leading experts as they discuss the controversies in a highly interactive program with case presentations, surgical videos and panel discussions.

#### Key Features

- Find out strategies to optimize imaging for pre-operative diagnosis of endometriosis, adenomyosis and fibroids.
- Learn what's new with surgical and medical approaches to management of these conditions in patients with infertility and pain.
- Incorporate treatment algorithms into your clinical practice.

#### Program Directors



**Rosanne Kho, MD**  
Director, Benign Gynecologic Surgery  
Department of Obstetrics and Gynecology  
Obstetrics, Gynecology and Women's Health Institute  
Cleveland Clinic  
Cleveland, OH



**Mary Jean Uy-Kroh, MD**  
Assistant Professor of Surgery  
Women's Health Institute and Surgical  
Subspecialty Institute  
Cleveland Clinic Abu Dhabi  
Abu Dhabi, United Arab Emirates

This activity has been approved for AMA PRA Category 1 Credits™.

Register today! [ccfcmec.org/ceaf17](http://ccfcmec.org/ceaf17)