

High-Yield Biopsy Technique for Subepidermal Blisters

Mark A. Braswell, BS; Nancye K. McCowan, MD; Jennifer S. Schulmeier, MD; Robert T. Brodell, MD

Practice Points

- Allergic contact dermatitis, pemphigoid, dermatitis herpetiformis, acquired epidermolysis bullosa, and porphyria cutanea tarda produce tense blisters.
- Biopsy of the edge point of a tense blister localizes immunoglobulin to the floor versus the roof on direct immunofluorescence.
- A punch biopsy should include 75% perilesional skin at the edge of a blister.
- Marking the blister with a skin marker will assure that the tissue is properly oriented when bisected at the bedside.

Dermatologists often perform 2 biopsies in patients with widespread tense blisters: one for light microscopy and another for direct immunofluorescence (DIF). Biopsy techniques recommended for blistering diseases with tense blisters are discussed, and illustrations demonstrate an alternative approach utilizing a single punch biopsy. A single punch biopsy is more cost effective and provides the same diagnostic information as the standard 2-biopsy approach for subepidermal blisters plus additional salt-split skin-like diagnostic information. A limitation for bisecting the single punch biopsy specimen is a potential complete separation of the epidermis from the dermis. The single punch biopsy technique is a simple cost-effective method for obtaining necessary diagnostic information when sampling tense blisters in patients with blistering diseases.

Cutis. 2015;95:237-240.

Mr. Braswell is from Kansas City University of Medicine and Biosciences, Missouri. Drs. McCowan and Brodell are from the Division of Dermatology, University of Mississippi Medical Center, Jackson. Dr. Schulmeier is from Dermatopathology Associates, Jackson.

The authors report no conflict of interest.

Correspondence: Robert T. Brodell, MD, Division of Dermatology, University of Mississippi Medical Center, 2500 N State St, Jackson, MS 39216 (rbrodell@umc.edu).

The traditional approach for confirming the diagnosis of subepidermal blistering diseases such as bullous pemphigoid (BP), epidermolysis bullosa acquisita (EBA), dermatitis herpetiformis (DH), and linear IgA bullous dermatosis (LABD) requires 2 punch biopsies: one from perilesional skin for direct immunofluorescence (DIF) and one from lesional skin for light microscopy using hematoxylin and eosin (H&E) stain.¹⁻⁴ These conditions are distinguished by a combination of features appreciated on H&E-stained sections, DIF, and indirect immunofluorescence for a subset of disorders. Additional information may be provided by DIF or indirect immunofluorescence utilizing the salt-split skin technique to differentiate BP (in which linear IgG deposition is identified by immunofluorescence on the roof of salt-split skin) from EBA and antiepiligrin cicatricial pemphigoid (in which linear IgG deposition is identified by immunofluorescence along the floor of the salt-split skin), which is more rare.⁴ One bisected punch biopsy of a subepidermal blister yields salt-split skin-like information through standard DIF and supersedes the need for the more cumbersome salt-split skin technique.

Serologic tests for the presence of circulating antibodies to BP180 and BP230 represent an emerging technology that can confirm the diagnosis of BP, but it has been difficult to identify clinically useful autoantibodies to confirm diagnoses of EBA and LABD.⁵⁻⁷ Serologic tests for tissue transglutaminase

IgA antibodies may be useful in the diagnosis of DH.⁸ We present a cost-effective approach to biopsy in the diagnosis of subepidermal blistering diseases that provides the necessary diagnostic information to distinguish relevant disease processes.

Subepidermal Blistering Diseases

Bullous pemphigoid commonly presents with widespread tense bullae of varying sizes on an erythematous base or on otherwise normal skin.⁹ Some cases of BP present not with bullae but with pruritic, urticarial, plaquelike, or papular lesions. Bullous pemphigoid commonly involves flexural surfaces and the trunk but can appear anywhere on the skin. The induction of blisters by shearing with mechanical pressure on perilesional skin (Nikolsky sign) is not characteristically present in BP as it is in pemphigus vulgaris.¹⁰ Epidermolysis bullosa acquisita can mimic BP in the development of widespread tense bullae, but blisters typically appear on areas of the skin that are prone to trauma (eg, toes, knees, elbows, hands). Crusted erosions, scarring, and milia also are clinical manifestations of EBA.¹¹ Dermatitis herpetiformis presents with grouped vesicles, papulovesicles, plaques, and excoriations that are symmetrically distributed on extensor surfaces of the skin but also can occur on the buttocks, scalp, and other areas of the skin.^{12,13} Although it may mimic both BP and DH, LABD frequently is less pruritic than these other conditions.^{14,15} Linear IgA bullous dermatosis also demonstrates the characteristic finding of multiple bullae that form concentrically around a crusted area of skin. This physical finding is known as a string of pearls. Linear IgA bullous dermatosis typically occurs in childhood and may resolve without treatment in months to years.¹⁶

Traditional Biopsy Approach

A review of several articles from the literature and multiple dermatology and dermatopathology textbooks revealed uniform recommendations for biopsy of subepidermal blistering conditions that manifest as tense blisters.^{1-4,9-23} A biopsy of early lesional skin or of a blister for light microscopy with H&E stain and biopsy of perilesional skin for DIF is recommended.^{1-4,9-23} Three review articles specifically suggested biopsy of “perilesional skin” for DIF.¹⁻³ The majority of textbooks we reviewed also suggested that perilesional skin, or skin adjacent to a zone of erythema in the case of DH, should be sampled for DIF to assist in the diagnosis of BP, EBA, DH, and LABD.^{4,9-21} Biopsy of adjacent or nonlesional skin or skin around the lesion for DIF also was recommended by other textbooks for diagnosis of subepidermal blistering diseases.^{22,23} Perilesional skin is chosen because it is critical that the epidermis be included

for adequate immunofluorescence studies.^{5,20} Biopsy of healed and crusted lesions should be avoided.²⁴

Recommended Alternative Approach

A single punch biopsy produces the best possible specimen for light microscopy with H&E stain and DIF if it is obtained via one of 2 methods.

The first method involves choosing a small, 1- to 2-mm tense blister.²⁵ Use an 8-mm punch centered on the blister that includes at least 3 mm of circumferential perilesional skin (Figures 1 and 2).²⁰ Holding the specimen with forceps, use a no. 15 scalpel blade to bisect the blister with a sawing motion. Place half of the specimen in formalin for H&E staining and the other half in Zeus (or Michel) medium for DIF (Figure 3).

The second method is to choose any large blister and, utilizing a surgical marker, draw a line from the roof of the blister onto the adjacent perilesional skin (Figure 1).^{20,24} After blotting with an alcohol pad so as not to remove the mark, anesthetize the site with lidocaine 1% with epinephrine,²⁴ then take an 8-mm punch biopsy encompassing 75% perilesional skin

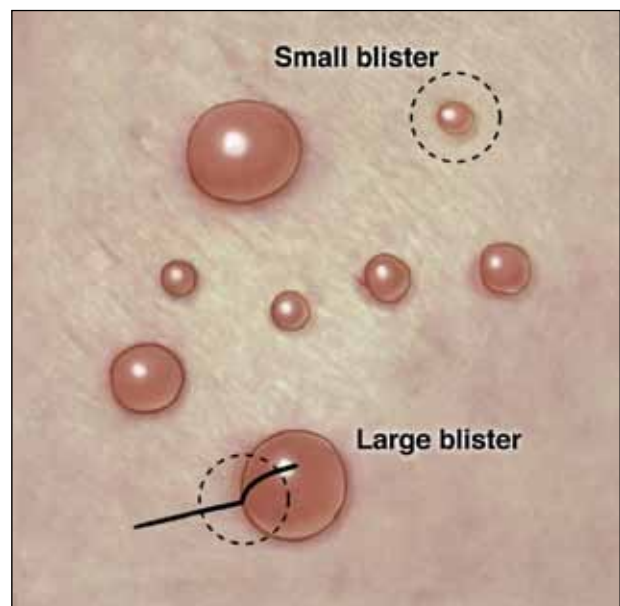


Figure 1. Punch biopsy of subepidermal blisters. For large blisters, a line is drawn with a surgical marker from the roof of the tense blister onto the surrounding perilesional skin. A punch biopsy is obtained from the edge of the blister with approximately 75% of the sample representing perilesional skin. For smaller blisters, the entire blister is punch excised. Illustration by W. Kyle Cunningham, Biomedical Illustration Services at the University of Mississippi Medical Center (Jackson, Mississippi).

and 25% of the blister centered on the line (Figure 2). After separating the punch specimen from the subcutaneous tissue with surgical scissors, hold the tissue with forceps and bisect the specimen with a no. 15 scalpel blade. Use a sawing motion along the line drawn in the prior steps. Submit half of the biopsy for H&E staining in formalin and the other half for DIF in Zeus (or Michel) medium (Figure 3).

Advantages

This approach offers several advantages. First, when biopsying either a small or large tense blister with this technique, only 1 invasive procedure, not 2 separate biopsies, is required. Therefore, our proposed procedures can be done quickly and efficiently with the least morbidity and scarring. Secondly, because the patient is billed for 1 biopsy instead of 2, the single punch biopsy technique is more cost effective.

The bisected specimen resulting from complete excision of a small blister or from biopsy of a larger blister that includes 75% perilesional skin and 25% from the blister cavity also provides the best tissue specimen for interpretation of the subepidermal blistering processes via H&E staining.^{4,20,24} When traditional unmarked punch specimens of a blister margin are sent to the laboratory in formalin for H&E staining, the technician that grosses the specimen may or may not bisect the specimen demonstrating the edge of the blister at the point where the epidermis is separated from the papillary dermis.

Finally, when the DIF specimen is prepared using either of these 2 approaches, the immunoprecipitants can be seen at the dermoepidermal junction or in the papillary dermis in the perilesional portion of the specimen.^{2,4} Additionally, the immunoprecipitant

may be identified on the roof or floor of the blister. Although this approach has not been studied in a systematic fashion, we believe this technique provides “bonus” information (eg, the same information gained from salt-split skin indirect immunofluorescence to demonstrate if immunoprecipitants are deposited in the roof or floor of the blister).^{5,6}

Limitations

It is critical for the pathologist or technician grossing these specimens to understand this technique and ensure that the cut edge of each half punch specimen is properly embedded for both H&E and DIF specimens. Additionally, with either recommended technique, if the portion of perilesional skin is not sufficient and the epidermis completely separates from the dermis, interpretation of both the H&E staining and DIF sections is substantially compromised.²⁰ Therefore, an 8-mm disposable punch is recommended to avoid mangling the specimens when they are bisected and to ensure that the epithelium is not lost. This technique is less suitable for blistering processes with a positive Nikolsky sign, such as pemphigus and toxic epidermal necrolysis, because the small area of perilesional skin adjacent

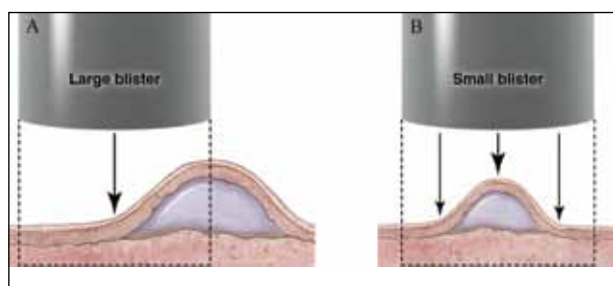


Figure 2. Punch biopsy of subepidermal blisters. Cross-sectional view showing sampling of a large blister with approximately 75% of the sample representing perilesional skin (A) and a small blister with at least 3 mm of perilesional skin included in the specimen (B). Illustration by W. Kyle Cunningham, Biomedical Illustration Services at the University of Mississippi Medical Center (Jackson, Mississippi).

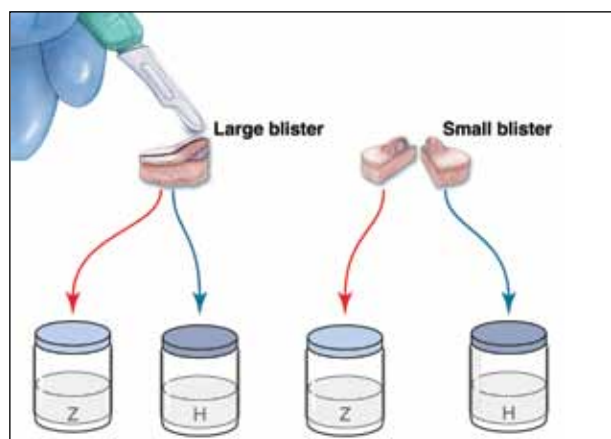


Figure 3. Punch biopsy of subepidermal blisters. Specimens from large blisters are bisected at the bedside with a no. 15 blade following the line drawn previously to ensure that perilesional skin and the “take-off point” of the blister (the edge of the blister at the point where the epidermis is separated from the papillary dermis) will be visible when the cut edge is properly embedded in the laboratory. Excisional punch biopsies of small blisters are simply bisected. Half of each specimen is placed in formalin for hematoxylin and eosin (H) processing, and half is placed in Zeus (Z) (or Michel) medium for direct immunofluorescence. Illustration by W. Kyle Cunningham, Biomedical Illustration Services at the University of Mississippi Medical Center (Jackson, Mississippi).

to the blister may detach completely, requiring the epidermis and dermis to be evaluated separately or, in the worst-case scenario, the epidermis may be lost in processing.

Conclusion

Bisecting a single punch biopsy on subepidermal blisters provides the best specimen for H&E staining and DIF. The single punch biopsy technique also differentiates BP and EBA without utilizing salt-split skin immunofluorescence studies. This technique is more efficient and cost effective than the traditional approach of multiple biopsies on subepidermal blisters.

REFERENCES

1. Kasperkiewicz M, Zillikens D, Schmidt E. Pemphigoid diseases: pathogenesis, diagnosis, and treatment. *Autoimmunity*. 2012;45:55-70.
2. Mihai S, Sitaru C. Immunopathology and molecular diagnosis of autoimmune bullous diseases. *J Cell Mol Med*. 2007;11:462-481.
3. Yeh SW, Ahmed B, Sami N, et al. Blistering disorders: diagnosis and treatment. *Dermatol Ther*. 2003;16:214-223.
4. Vesicular and bullous diseases. In: Habif TP. *Clinical Dermatology: A Color Guide to Diagnosis and Therapy*. 5th ed. Edinburgh, Scotland: Mosby Elsevier; 2010:635-670.
5. Schmidt E, della Torre R, Borradori L. Clinical features and practical diagnosis of bullous pemphigoid. *Dermatol Clin*. 2011;29:427-438.
6. Caux F. Diagnosis and clinical features of epidermolysis bullosa acquisita. *Dermatol Clin*. 2011;29:485-491.
7. Terra JB, Jonkman MF, Diercks GF, et al. Low sensitivity of type VII collagen enzyme-linked immunosorbent assay in epidermolysis bullosa acquisita: serration pattern analysis on skin biopsy is required for diagnosis. *Br J Dermatol*. 2013;169:164-167.
8. Plotnikova N, Miller JL. Dermatitis herpetiformis. *Skin Therapy Lett*. 2013;18:1-3.
9. Culton DA, Liu Z, Diaz LA. Bullous pemphigoid. In: Goldsmith LA, Katz SI, Gilchrist BA, et al, eds. *Fitzpatrick's Dermatology in General Medicine*. 8th ed. New York, NY: McGraw-Hill; 2012. <http://accessmedicine.mhmedical.com.proxy.kcumb.edu/content.aspx?bookid=392&Sectionid=41138755>. Accessed June 24, 2013.
10. Bernard P, Borradori L. Pemphigoid group. In: Bologna JL, Jorizzo JL, Schaffer JV, eds. *Dermatology*. 3rd ed. Edinburgh, Scotland: Saunders Elsevier; 2012:475-490.
11. Woodley DT, Chen M. Epidermolysis bullosa acquisita. In: Goldsmith LA, Katz SI, Gilchrist BA, et al, eds. *Fitzpatrick's Dermatology in General Medicine*. 8th ed. New York, NY: McGraw-Hill; 2012. <http://accessmedicine.mhmedical.com.proxy.kcumb.edu/content.aspx?bookid=392&Sectionid=41138759>. Accessed June 24, 2013.
12. Chronic blistering dermatoses. In: James WD, Berger TG, Elston DM. *Andrew's Diseases of the Skin*. 11th ed. London, England: Saunders Elsevier; 2011:448-467.
13. Ronaghy A, Katz SI, Hall RP. Dermatitis herpetiformis. In: Goldsmith LA, Katz SI, Gilchrist BA, et al, eds. *Fitzpatrick's Dermatology in General Medicine*. 8th ed. New York, NY: McGraw-Hill; 2012. <http://accessmedicine.mhmedical.com.proxy.kcumb.edu/content.aspx?bookid=392&Sectionid=41138760>. Accessed June 24, 2013.
14. Hull CM, Zone JJ. Dermatitis herpetiformis and linear IgA bullous dermatosis. In: Bologna JL, Jorizzo JL, Schaffer JV, eds. *Dermatology*. 3rd ed. Edinburgh, Scotland: Saunders Elsevier; 2012:491-500.
15. Rao CL, Hall RP III. Linear immunoglobulin a dermatosis and chronic bullous disease of childhood. In: Goldsmith LA, Katz SI, Gilchrist BA, et al, eds. *Fitzpatrick's Dermatology in General Medicine*. 8th ed. New York, NY: McGraw-Hill; 2012. <http://accessmedicine.mhmedical.com.proxy.kcumb.edu/content.aspx?bookid=392&Sectionid=41138757>. Accessed June 24, 2013.
16. Bullous disorders of childhood. In: Paller AS, Mancini AJ. *Hurwitz Clinical Pediatric Dermatology: A Textbook of Skin Disorders of Childhood and Adolescence*. 4th ed. Philadelphia, PA: Saunders Elsevier; 2011:303-320.
17. Inherited and autoimmune subepidermal blistering diseases. In: Caljone E, Brenn T, Lazar A, et al. *McKee's Pathology of the Skin: With Clinical Correlations*. 4th ed. Edinburgh, Scotland: Elsevier Saunders; 2012:99-150.
18. Elenitsas R, Ming ME. Biopsy techniques. In: Elder DE, Elenitsas R, Johnson BL Jr, et al, eds. *Lever's Histopathology of the Skin*. 10th ed. Philadelphia, PA: Lippincott Williams & Wilkins; 2008:5-6.
19. Wu H, Brandling-Bennett HA, Harrist TJ. Noninfectious vesiculobullous and vesiculopustular diseases. In: Elder DE, Elenitsas R, Johnson BL Jr, et al, eds. *Lever's Histopathology of the Skin*. 10th ed. Philadelphia, PA: Lippincott Williams & Wilkins; 2008:235-278.
20. Smoller BR, Kohler S. Subepidermal vesicular dermatitis. In: Barnhill RL, Crowson AN, eds. *Textbook of Dermatopathology*. New York, NY: McGraw-Hill; 2004:167-194.
21. Junkins-Hopkins JM, Busam KJ. Blistering skin diseases. In: Busam KJ, ed. *Dermatopathology*. 2nd ed. Philadelphia, PA: Saunders Elsevier; 2010:207-248.
22. High, WA. Blistering diseases. In: Elston DM, Ferringer T, Ko C, et al, eds. *Dermatopathology*. Edinburgh, Scotland: Saunders Elsevier; 2009:161-172.
23. The vesicobullous reaction pattern. In: Weedon D. *Weedon's Skin Pathology*. 3rd ed. Edinburgh, Scotland: Churchill Livingstone/Elsevier; 2009:93-148.
24. Alguire PC, Mathes BM. Skin biopsy techniques for the internist. *J Gen Intern Med*. 1998;13:46-54.
25. Sina B, Kao GF, Deng AC, et al. Skin biopsy for inflammatory and common neoplastic skin diseases: optimum time, best location and preferred techniques. a critical review. *J Cutan Pathol*. 2009;36:505-510.