



ANCA subsets: Influence on disease phenotype

ULRICH SPECKS, MD

Over the last decade a large body of evidence has accumulated linking antineutrophil cytoplasmic autoantibodies (ANCA) to the pathogenesis of the small vessel vasculitides Wegener's granulomatosis (WG) and microscopic polyangiitis (MPA). The concept of how ANCA directly and indirectly contribute to vascular injury is derived mostly from *in vitro* studies (Figure 1); it is not only plausible, but also consistent with clinical and animal model observations. Nevertheless, significant gaps in our knowledge remain, and the controversy whether ANCA cause disease manifestations or are merely a marker of the disease has yet to be settled. Answers to the following questions would represent major advances in our understanding of the pathogenesis of ANCA-associated vasculitis. 1) What triggers and what causes persistence of the ANCA response? 2) Why, of all ANCA, are only those directed against proteinase 3 (PR3) and myeloperoxidase (MPO) unequivocally linked to pauci-immune small vessel vasculitis? 3) Why does not every patient with PR3-ANCA or MPO-ANCA suffer from active vasculitis? The goal of this overview is not to provide answers to these questions, but to set the stage for the hypothesis that the answers will be found by unraveling the molecular (and functional) interactions between ANCA and their specific target antigens.

■ ANCA AND THE PATHOGENESIS OF VASCULITIS

ANCA were first described in the early 1980s as a cause of diffuse granular cytoplasmic immunofluorescence staining (C-ANCA) on ethanol-fixed neutrophils in association with glomerulonephritis, vasculitis and Wegener's granulomatosis (WG).^{1,2} PR3 was subsequently identified as the principal target antigen for these ANCA.³⁻⁶ At the same time, ANCA reacting with myeloperoxidase (MPO) causing a perinuclear immunofluorescence staining pattern on ethanol-fixed neutrophils (P-ANCA) were found in patients with MPA, its renal-limited variant, pauci-immune glomerulonephritis, and, less frequently, in WG.⁷ Multiple

other neutrophil granule constituents have since been identified as potential targets for ANCA in a variety of disorders (reviewed in reference 8). However, many large clinical studies have confirmed that only C-ANCA reacting with PR3 and P-ANCA reacting with MPO have a high specificity for the autoimmune vasculitides WG and MPA (reviewed in references 8 and 9).

Because of their high disease specificity and other clinical observations, PR3- and MPO-ANCA have been suspected to be more than an epiphenomenon. ANCA levels frequently correlate with disease activity, even though this correlation may not always be apparent in every individual patient (reviewed in reference 10). Prospective studies have confirmed the persistence or recurrence of ANCA and significant ANCA titer rises as independent risk factors for clinical relapses; also, a relapse of vasculitis activity in the absence of ANCA is extremely unusual.^{11,12} ANCA-negative patients with biopsy-proven WG usually have a good prognosis and do not develop systemic vasculitic complications until there is ANCA seroconversion.¹³ Patients receiving drugs such as propylthiouracil, hydralazine or allopurinol, which are known to induce autoantibodies and clinical autoimmune syndromes, may develop high titers of MPO-ANCA and small vessel vasculitis.¹⁴ These clinical observations all support a significant contributory role of ANCA for the development of small vessel vasculitis.

Over the past decade many *in vitro* experiments and some animal model studies have been performed to better understand the pathogenic role of ANCA and to identify specific mechanisms by which ANCA may lead to vascular injury (reviewed in references 15 to 17). Many proinflammatory effects of ANCA on neutrophils, monocytes, and endothelial cells which enhance and perpetuate endothelial cell and tissue damage have been well documented. The pathogenic role of ANCA for the development of vasculitis is also supported by animal models of MPO-ANCA-associated vasculitis (reviewed in reference 16). They clearly indicate that ANCA contribute directly to the development of vasculitis and glomerulonephritis and that the interaction of ANCA with its target antigen is required for the development of lesions. Furthermore, the localization of lesions is determined by the site of this interaction. At the same time, animal models support the significance of genetic determinants for the

From the Division of Pulmonary and Critical Care Medicine, Mayo Clinic and Foundation, Rochester, MN.

Address correspondence to U.S., Division of Pulmonary and Critical Care Medicine, Mayo Clinic and Foundation, 200 First Street SW, Rochester, MN 55905.

E-mail: specks.ulrich@mayo.edu

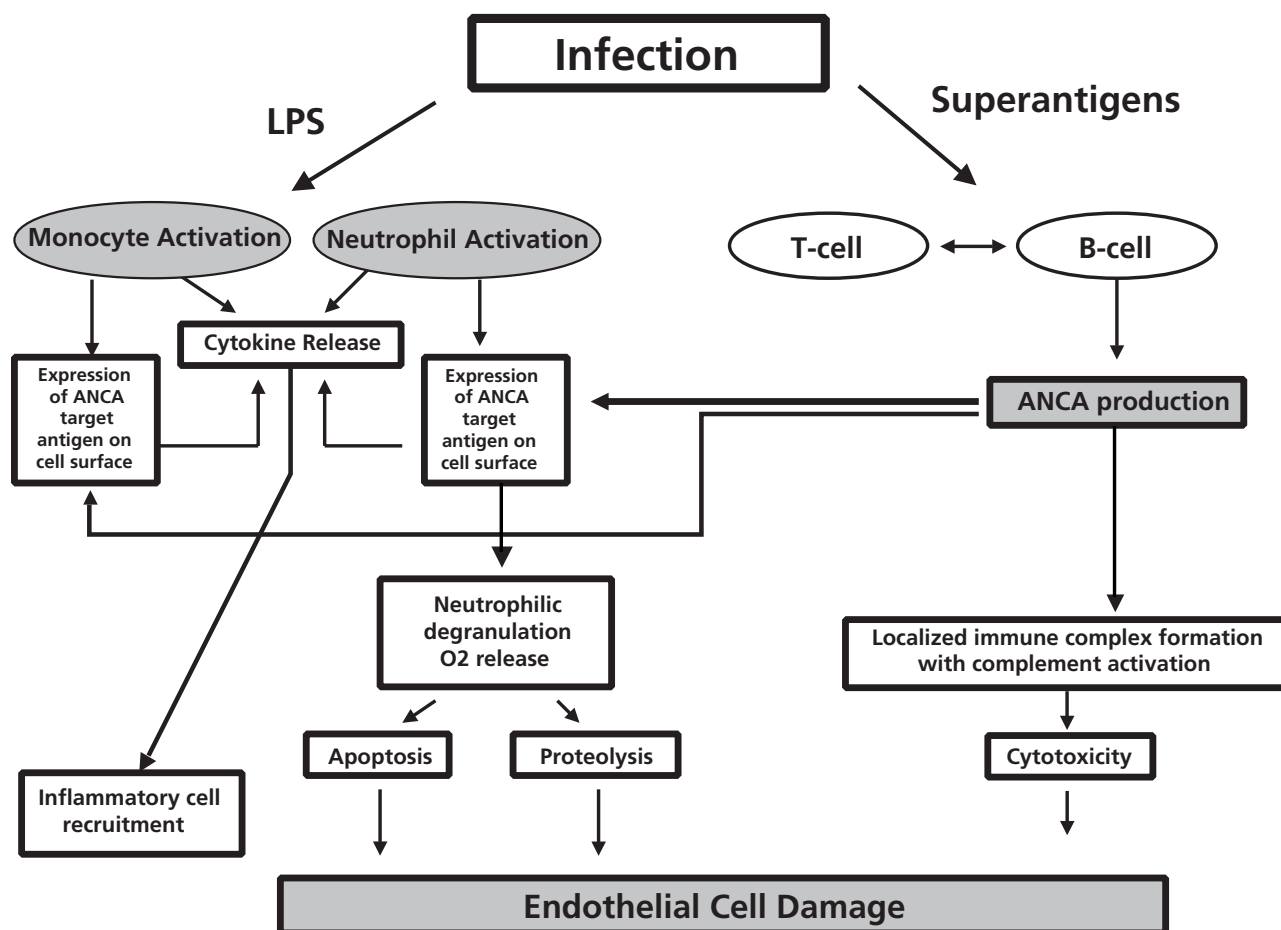


Figure 1. Schematic concept of proinflammatory effects of ANCA leading to vasculitis. Cofactors such as infections can trigger an inflammatory response leading to cytokine-mediated priming of monocytes and neutrophils. This results in cell surface expression of ANCA target antigens (such as PR3), which then may become a target for circulating ANCA. ANCA production may be the result of interactions between T cells and B cells, activated by microbial superantigens. Stimulation of primed neutrophils and monocytes by ANCA induces degranulation with protease release, and a respiratory burst with release of radical oxygen species. These effects result in direct injury to endothelial cells. Invoked mechanisms include cytotoxicity and apoptosis, but also localized immune complex formation with complement activation. LPS = lipopolysaccharide; ANCA = antineutrophil cytoplasmic antibodies.

development of autoimmunity, vasculitis, and a specific phenotype with characteristic organ involvement and histopathologic features. Finally, animal model studies indicate that infections may be significant disease modifiers.^{18,19} Thus, the data from existing animal models of ANCA-associated vasculitis are fully consistent with the pathogenic concept of ANCA depicted in Figure 1.

Does the type of ANCA matter?

The mechanisms of ANCA induction and of their subsequent persistence remain unknown. ANCA directed against a variety of target antigens have been reported in infections with bacterial, mycobacterial, fungal, viral and parasitic organisms (reviewed in reference 8). However, positivity for c-ANCA reacting with PR3 and for p-ANCA reacting with MPO is highly specific for small vessel vasculitis and extremely uncommon in infections. Nevertheless, c-ANCA/PR3-ANCA have been reported in amebiasis as well as subacute bacterial endocarditis

(SBE).^{20,21} In both instances the ANCA disappeared with appropriate antimicrobial therapy, suggesting that ANCA may occur transiently in the setting of infection, and that the persistent ANCA response in patients with vasculitis may be the result of molecular mimicry in susceptible hosts.²² Subsequent diversification of T- and B-cell responses (“epitope spreading”) may lead to responses against different epitopes on the same target molecule (intra-molecular spreading) or extend to other molecules (inter-molecular spreading).²³

It is therefore an attractive hypothesis that infections may trigger an initial ANCA-response. If it happens to be directed against the “right” molecules, ie, PR3 or MPO, and is allowed to persist, the stage is set for the subsequent development of small vessel vasculitis. Even though it is currently unclear what makes these two antigens so unique among all the described ANCA target antigens that only ANCA against these two are tightly associated with small vessel vasculitis, the ANCA target antigen

specificities seem to have a bearing on clinical disease manifestations. Whereas WG is mostly associated with c-ANCA/PR3-ANCA,^{24,25} the majority of MPA patients have p-ANCA/MPO-ANCA.²⁶ A direct comparison of clinical features of patients categorized by their ANCA-status revealed that extra-renal manifestations, granuloma formation, and relapse were more frequent in patients with PR3-ANCA than those with MPO-ANCA.²⁷ In patients with pauci-immune glomerulonephritis and MPA, the relative risk of death was 3.78 times greater in patients with c-ANCA than in those with p-ANCA. Most individual histopathologic lesions, and particularly the capillaritis of the lung and the focal segmental necrotizing glomerulonephritis, do not allow a distinction between MPO-ANCA-associated disease and PR3-ANCA-associated disease per se. Yet the characteristic necrotizing granulomatous (“geographic necrosis”) inflammation with giant cells of WG is rarely encountered in patients with MPO-ANCA.^{28,29} A careful analysis of renal biopsy specimens of 173 patients obtained at the time of diagnosis suggests that active and chronic renal lesions are more abundant in MPO-ANCA-positive patients than in PR3-ANCA positive patients,³⁰ confirming previous observations made by others in a smaller cohort of patients.³¹ Thus, despite substantial overlap, there appear to be clinical and pathologic differences between patients with PR3-ANCA and MPO-ANCA that may reflect different pathogenic interactions between ANCA, their target antigens, and the target organ environment at the molecular level.

Why does not everybody with PR3- or MPO-ANCA have active vasculitis?

The clinical observation that not everybody with a PR3-ANCA or MPO-ANCA develops a small vessel vasculitis appears to be at odds with the concept of the pathogenicity of these ANCA. Even the best-standardized ANCA detection methods occasionally identify false-positive results. The best-documented false-positive C-ANCA/PR3-ANCA are the already mentioned 7 patients with SBE (only one of whom also had proven vasculitis).²¹ Another important clinical observation is that not every vasculitis patient with ANCA relapses when ANCA recur or persist.^{12,32} This and the fact that the ANCA of the SBE patients disappeared promptly after successful antibiotic therapy might suggest that “pathogenic” ANCA need to persist long enough for subsequent

exposure of the patient to cofactors (such as infection or wound healing) that via neutrophil and monocyte priming allow for ANCA to interact with their target antigen on the effector cell surface and trigger the cascade leading to endothelial cell damage (Figure 1).

Another possible explanation is that ANCA subsets, which are not differentiated by routine methods of ANCA detection, interact differently with their target antigens, resulting in variable functional consequences. Competition studies using different monoclonal antibodies have shown that sera from patients contain variable amounts of PR3-ANCA subsets recognizing different epitopes.³³ Furthermore, some PR3-ANCA interfere with the complexation of PR3 with its inhibitor, alpha 1-PI, and some directly inhibit the enzymatic activity of PR3. In these small patient series, PR3-ANCA with these properties seemed to be associated disease activity.³⁴⁻³⁶ The notion that some PR3-ANCA recognizing specific epitopes may be more relevant for the pathogenesis of vasculitis than others is also supported by our observation that PR3-ANCA encountered in cocaine abusers with midline destructive lesions, but no vasculitis, seem to be different from those found in WG patients.³⁷ Furthermore, we have shown that PR3-ANCA subsets recognizing conformational epitopes on the pro-form of PR3 may be more sensitive to changes in disease activity than PR3-ANCA reacting with epitopes only accessible on the mature form of PR3.³⁸ ANCA recognizing different epitopes on MPO have also been reported,^{39,40} and certain epitope recognition profiles seem to be related to clinical disease manifestations.⁴¹ Finally, ANCA of different IgG subclass may affect the clinical disease manifestations. Enrichment of IgG3 subclass ANCA has been observed in patients with active disease.^{12,42,43} IgG3 is the most effective complement activator and binds with high affinity to Fc receptors on neutrophils and monocytes.

These observations support the hypothesis that specific ANCA subsets may contribute to the heterogeneity of clinical manifestations via their different functional effects on their target antigens and inflammatory cells. At the same time, ANCA subsets may also explain apparent incongruences between ANCA test results and clinical findings. More definitive studies aimed at the identification of specific ANCA subsets, their functional impact and clinical correlations in large well-characterized patient populations allowing detailed statistical analysis with sufficient power are needed.

■ REFERENCES

- Davies DJ, Moran JE, Niall JF, Ryan GB. Segmental necrotizing glomerulonephritis with antineutrophil antibody: possible arbovirus aetiology. *Br Med J* 1982; 285:606.
- van der Woude FJ, Rasmussen N, Lobatto S, Wiik A, Perman H, van Es LA, van der Giessen M, van der Hem GK, The TH. Autoantibodies against neutrophils and monocytes: tool for diagnosis and marker of disease activity in Wegener's granulomatosis. *Lancet* 1985; 1:425-429.
- Goldschmeding R, van der Schoot CE, ten Bokkel Huinink D, Hack CE, van den Ende ME, Kallenberg CGM, van dem Borne AEGK. Wegener's granulomatosis autoantibodies identify a novel diisopropylfluorophosphate-binding protein in the lysosomes of normal human neutrophils. *J Clin Invest* 1989; 84:1577-1587.
- Jenne DE, Tschopp J, Lüdemann J, Utecht B, Gross WL. Wegener's autoantigen decoded. *Nature* 1990; 346:520.
- Lüdemann J, Utecht B, Gross WL. Anti-neutrophil cytoplasm antibodies in Wegener's granulomatosis recognize an elastinolytic enzyme. *J Exp Med* 1990; 171:357-362.
- Niles JL, McCluskey RT, Ahmad MF, Arnaout MA. Wegener's granulomatosis autoantigen is a novel neutrophil serine proteinase. *Blood* 1989; 74:1888-1893.
- Falk RJ, Jennette JC. Anti-neutrophil cytoplasmic autoantibodies with specificity for myeloperoxidase in patients with systemic vasculitis and idiopathic necrotizing and crescentic glomerulonephritis. *N Engl J Med* 1988; 25:1651-1657.
- Hoffman GS, Specks U. Anti-neutrophil cytoplasmic antibodies. *Arthritis Rheum* 1998; 41:1521-1537.
- Savage J, Davies D, Falk RJ, Jennette JC, Wiik A. Antineutrophil cytoplasmic antibodies and associated diseases: a review of the clin-

- ical and laboratory features. *Kidney Int* 2000; 57:846-862.
10. Cohen Tervaert JW, Stegeman CA, Kallenberg CGM. Serial ANCA testing is useful in monitoring disease activity of patients with ANCA-associated vasculitides. *Sarcoidosis Vasc Diffuse Lung Dis* 1996; 13:241-245.
 11. Stegeman CA, Cohen Tervaert JW, de Jong PE, Kallenberg CG. Trimethoprim-sulfamethoxazole (co-trimoxazole) for the prevention of relapses of Wegener's granulomatosis. *N Engl J Med* 1996; 335:16-20.
 12. Boomsma MM, Stegeman CA, van der Leij MJ, Oost W, Hermans J, Kallenberg CGM, Limburg PC, Cohen Tervaert JW. Prediction of relapses in Wegener's granulomatosis by measurement of antineutrophil cytoplasmic antibody levels. A prospective study. *Arthritis Rheum* 2000; 43:2025-2033.
 13. Chiba M, Specks U. Prognosis of Wegener's granulomatosis limited to the respiratory tract: significance of c-ANCA [abstract]. *Chest* 1996; 110:25S.
 14. Choi HK, Merkel PA, Walker AM, Niles JL. Drug-associated antineutrophil cytoplasmic antibody-positive vasculitis: prevalence among patients with high titers of antimyeloperoxidase antibodies. *Arthritis Rheum* 2000; 43:405-413.
 15. Hewins P, Tervaert JW, Savage CO, Kallenberg CG. Is Wegener's granulomatosis an autoimmune disease? *Curr Opin Rheumatol* 2000; 12:3-10.
 16. Specks U. Are animal models of vasculitis suitable tools? *Curr Opin Rheumatol* 2000; 12:11-19.
 17. Russell KA, Specks U. Are antineutrophil cytoplasmic antibodies pathogenic? Experimental approaches to understand the antineutrophil cytoplasmic antibody phenomenon. *Rheum Dis Clin North Am* 2001; 27:815-832.
 18. Harper JM, Thiru S, Lockwood CM, Cooke A. Myeloperoxidase autoantibodies distinguish vasculitis mediated by anti-neutrophil cytoplasm antibodies from immune complex disease in MRL/Mp-*lpr/lpr* mice: a spontaneous model for human microscopic angiitis. *Eur J Immunol* 1998; 28:2217-2226.
 19. Mathieson PW, Thiru S, Oliveira DB. Mercuric chloride-treated brown Norway rats develop widespread tissue injury including necrotizing vasculitis. *Lab Invest* 1992; 67:121-129.
 20. Pudifin DJ, Duursma J, Gathiram V, Jackson TFHG. Invasive amoebiasis is associated with the development of anti-neutrophil cytoplasmic antibody. *Clin Exp Immunol* 1994; 97:48-51.
 21. Choi HK, Lamprecht P, Niles JL, Gross WL, Merkel PA. Subacute bacterial endocarditis with positive cytoplasmic antineutrophil cytoplasmic antibodies and anti-proteinase 3 antibodies. *Arthritis Rheum* 2000; 43:226-231.
 22. Albert LJ, Inman RD. Molecular mimicry and autoimmunity. *N Engl J Med* 1999; 341:2068-2074.
 23. Craft J, Fatenejad S. Self antigens and epitope spreading in systemic autoimmunity. *Arthritis Rheum* 1997; 40:1374-1382.
 24. Hoffman GS, Kerr GS, Leavitt RY, Hallahan CW, Lebovics RS, Travis WD, Rottem M, Fauci AS. Wegener granulomatosis: an analysis of 158 patients. *Ann Intern Med* 1992; 116:488-498.
 25. Reinhold-Keller E, Beuge N, Latza U, de Groot K, Rudert H, Nolle B, Heller M, Gross WL. An interdisciplinary approach to the care of patients with Wegener's granulomatosis: long-term outcome in 155 patients. *Arthritis Rheum* 2000; 43:1021-1032.
 26. Guillevin L, Durand-Gasselin B, Cevallos R, Gayraud M, Lhote F, Callard P, Amouroux J, Casassus P, Jarrousse B. Microscopic polyangiitis: clinical and laboratory findings in eighty-five patients. *Arthritis Rheum* 1999; 42:421-430.
 27. Franssen C, Gans R, Kallenberg C, Hageluken C, Hoorntje S. Disease spectrum of patients with antineutrophil cytoplasmic autoantibodies of defined specificity: distinct differences between patients with anti-proteinase 3 and anti-myeloperoxidase autoantibodies. *J Intern Med* 1998; 244:209-216.
 28. Fienberg R, Mark EJ, Goodman M, McCluskey RT, Niles JL. Correlation of antineutrophil cytoplasmic antibodies with the extrarenal histopathology of Wegener's (pathergic) granulomatosis and related forms of vasculitis. *Hum Pathol* 1993; 24:160-168.
 29. Gaudin PB, Askin FB, Falk RJ, Jennette JC. The pathologic spectrum of pulmonary lesions in patients with anti-neutrophil cytoplasmic autoantibodies specific for anti-proteinase 3 and anti-myeloperoxidase. *Am J Clin Pathol* 1995; 104:7-16.
 30. Hauer HA, Bajema IM, van Houwelingen HC, Ferrario F, Noel LH, Waldherr R, Jayne DR, Rasmussen N, Bruijn JA, Hagen EC. Renal histology in ANCA-associated vasculitis: differences between diagnostic and serologic subgroups. *Kidney Int* 2002; 61:80-89.
 31. Franssen CF, Gans RO, Arends B, Hageluken C, ter Wee PM, Gerlag PG, Hoorntje SJ. Differences between anti-myeloperoxidase- and anti-proteinase 3-associated renal disease. *Kidney Int* 1995; 47:193-199.
 32. Girard T, Mahr A, Noel LH, Cordier JF, Lesavre P, Andre MH, Guillevin L. Are antineutrophil cytoplasmic antibodies a marker predictive of relapse in Wegener's granulomatosis? A prospective study. *Rheumatology (Oxford)* 2001; 40:147-151.
 33. Sommarin Y, Rasmussen N, Wieslander J. Characterization of monoclonal antibodies to proteinase 3 and application in the study of epitopes for classical anti-neutrophil cytoplasm antibodies. *Exp Nephrol* 1995; 3:249-256.
 34. van de Wiel BA, Dolman KM, van der Meer-Gerritsen CH, Nack CE, von dem Borne AEGK, Goldschmeding R. Interference of Wegener's granulomatosis autoantibodies with neutrophil proteinase 3 activity. *Clin Exp Immunol* 1992; 90:409-414.
 35. Dolman KM, Stegeman CA, van de Wiel BA, Hack CE, Von dem Borne AEGK, Kallenberg CGM, Goldschmeding R. Relevance of classic anti-neutrophil cytoplasmic autoantibody (C-ANCA)-mediated inhibition of proteinase 3-a1-antitrypsin complexation to disease activity in Wegener's granulomatosis. *Clin Exp Immunol* 1993; 93:405-410.
 36. Daouk GH, Palsson R, Arnaout MA. Inhibition of proteinase 3 by ANCA and its correlation with disease activity in Wegener's granulomatosis. *Kidney Int* 1995; 47:1528-1536.
 37. Trimarchi M, Gregorini G, Facchetti F, Morassi ML, Manfredini C, Maroldi R, Nicolai P, Russell KA, McDonald TJ, Specks U. Cocaine-induced midline destructive lesions: clinical, radiographic, histopathologic, and serologic features and their differentiation from Wegener granulomatosis. *Medicine* 2001; 80:391-404.
 38. Russell KA, Fass DN, Specks U. Antineutrophil cytoplasmic antibodies reacting with the pro form of proteinase 3 and disease activity in patients with Wegener's granulomatosis and microscopic polyangiitis. *Arthritis Rheum* 2001; 44:463-468.
 39. Audrain MAP, Baranger TAR, Moguilevski N, Martin SJ, Devys A, Lockwood CM, Muller JY, Esnault VLM. Anti-native and recombinant myeloperoxidase monoclonals and human autoantibodies. *Clin Exp Immunol* 1997; 107:127-134.
 40. Tomizawa K, Mine E, Fujii A, Ohashi YY, Yamagoe S, Hashimoto Y, Ishida-Okawara A, Ito M, Tanokura M, Yamamoto T, Arimura Y, Nagasawa T, Mizuno S, Suzuki K. A panel set for epitope analysis of myeloperoxidase (MPO)-specific antineutrophil cytoplasmic antibody MPO-ANCA using recombinant hexamer histidine-tagged MPO deletion mutants. *J Clin Immunol* 1998; 18:142-152.
 41. Fujii A, Tomizawa K, Arimura Y, Nagasawa T, Ohashi YY, Hiyama T, Mizuno S, Suzuki K. Epitope analysis of myeloperoxidase (MPO) specific anti-neutrophil cytoplasmic autoantibodies (ANCA) in MPO-ANCA-associated glomerulonephritis. *Clin Nephrol* 2000; 53:242-252.
 42. Esnault VL, Jayne DR, Weetman AP, Lockwood CM. IgG subclass distribution and relative functional affinity of anti-myeloperoxidase antibodies in systemic vasculitis at presentation and during follow-up. *Immunology* 1991; 74:714-718.
 43. Jayne DR, Weetman AP, Lockwood CM. IgG subclass distribution of autoantibodies to neutrophil cytoplasmic antigens in systemic vasculitis. *Clin Exp Immunol* 1991; 84:476-481.