

Parsonage-Turner syndrome: an unusual cause of hemidiaphragmatic paralysis

Patrick J. Sweeney, M.D.
Asa J. Wilbourn, M.D.

Department of Neurology

Muzaffar Ahmad, M.D.

Department of Pulmonary Disease

John P. Conomy, M.D.

Department of Neurology

Parsonage-Turner syndrome is a well-defined, idiopathic neurological disorder characterized by abrupt onset of unilateral shoulder girdle and arm pain followed by weakness, wasting and atrophy of the proximal or, occasionally, distal musculature of the involved extremity. Several unusual features of the syndrome have been described.¹ In this report, we present another of these variations, hemidiaphragmatic paralysis.

Case report

A 42-year-old right-handed woman presented for evaluation of right shoulder and arm pain. Six weeks earlier she had suffered from a flulike illness characterized by fever, myalgia and nausea. Shortly thereafter, she experienced neck pain, which radiated across the epaulet of the right shoulder into the shoulder itself and subsequently down into the right arm and right anterior chest. The pain was initially severe, requiring narcotic analgesics for relief. Two weeks after the onset of discomfort, she experienced weakness in the right upper extremity. She had been treated for arterial hypertension in the past. She was initially hospitalized at another institution for suspected cervical disc disease and cervical radiculopathy.

General admission physical examination revealed an alert, cooperative, pleasant woman complaining of pain and weakness in the right arm. The blood pressure varied between 180/110 and 160/110 mm Hg. The general

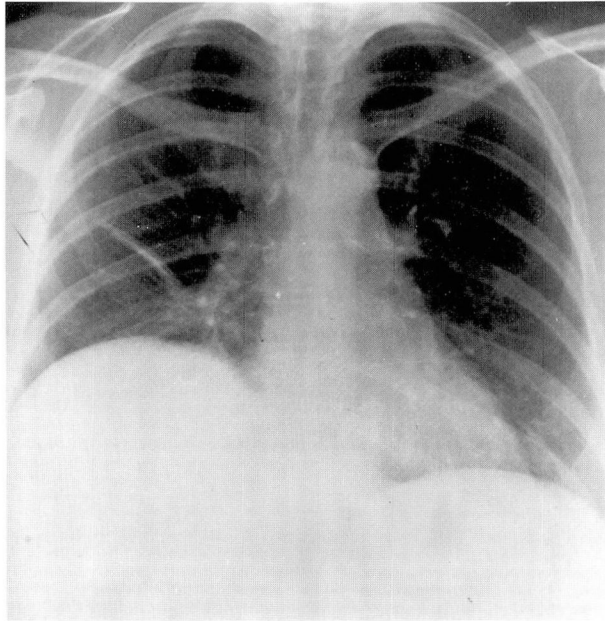


Fig. 1. Admission PA view of the chest shows elevated right hemidiaphragm.

physical examination was otherwise within normal limits. Neurologic abnormalities consisted of early hypertensive retinal change noted in both fundi. Weakness was noted in the right supraspinatus, deltoid, biceps and serratus anterior with winging of the right scapula. Right biceps reflex was absent.

Admission chest radiograph showed elevation and fixation of the right hemidiaphragm (*Fig. 1*). (A plain film of the chest taken 18 months earlier had demonstrated normal position of the diaphragm.) Paradoxical motion was observed at fluoroscopy. Plain films of the cervical spine, myelograms, and CSF examination were unremarkable.

Extensive electromyography (EMG) was performed. The motor amplitudes recording deltoid and biceps were borderline low; otherwise, all motor and sensory nerve conduction study results were well within the normal range. On needle examination, fibrillations and severe motor unit potential loss were seen in the right serratus anterior, with lesser but similar changes in the right biceps, deltoid, infraspinatus and supraspinatus muscles. Although the EMG findings were consistent with both a right C₆

radiculopathy and acute brachial plexitis, the latter was considered the more likely possibility because of the following: (1) absence of fibrillations in cervical paraspinal muscles; (2) abundant fibrillations and motor unit potential loss in the serratus anterior; and (3) clinical winging of the scapula.

Discussion

The brachial plexus (*Fig. 2*) is formed by the ventral rami of C₅₋₈ and T₁ with variable contributions from C₄ and T₂. At the lateral border of the scalenus muscles, the roots unite to form the upper, middle and lower trunks of the plexus. These subsequently divide behind the clavicle to form cords that ultimately disperse into the upper axilla as the major nerve trunks to the shoulders, upper chest, back and arms. The phrenic nerve derives primarily from C₄ with contributions from C₃ and C₅ as well; it provides the major motor innervation to the diaphragm.

Parsonage-Turner syndrome has a va-

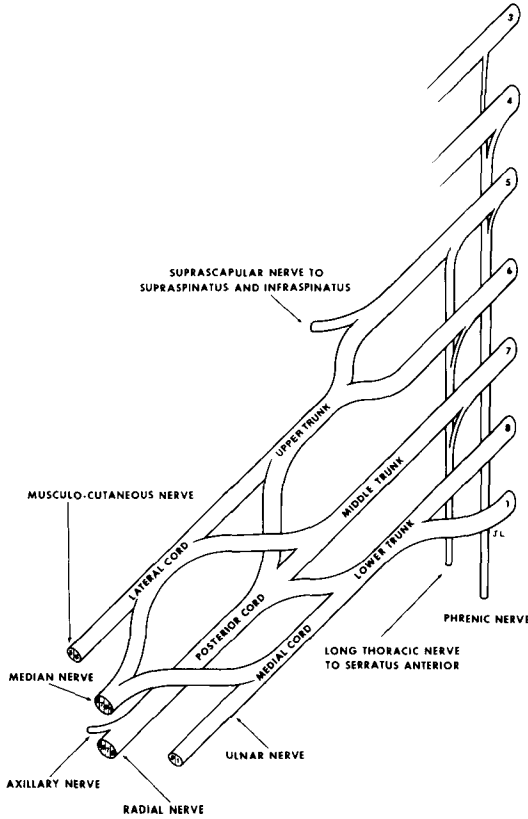


Fig. 2. Simplified scheme of the anatomy of the brachial plexus.

riety of rubrics, the most common being idiopathic brachial plexopathy. In 1943, Spillane² was the first to delineate the disorder, followed by Parsonage and Turner³ in 1948 who described the 136 cases that constituted their entire World War II experience with the syndrome. It has been described following nonspecific upper respiratory tract infections, vaccination, and administration of foreign sera, the latter circumstance raising the possibility of allergic mechanisms. The disorder may be viral in etiology.⁴

The predominant symptom is abrupt onset of severe shoulder girdle pain followed by weakness and atrophy of the shoulder girdle musculature and loss of appropriate reflexes. The majority of

patients are between the third and seventh decades in age, with a male predominance of 2.5 to 1. An afebrile illness, it is not associated with systemic signs. The most common nerve-muscle involvement has been the serratus anterior (long thoracic nerve), supraspinatus and infraspinatus (suprascapular nerve), deltoid (circumflex-axillary nerve), biceps (musculocutaneous nerve), and triceps (radial nerve).

The differential diagnosis includes cervical spondylosis, cervical radiculopathy, extradural tumor, and primary rotator cuff injuries of the shoulder joint.

Several other conditions resulting in phrenic nerve injury must also be considered: (1) lung carcinoma; (2) sur-

gically induced atelectasis, or thoracotomy for pulmonary tuberculosis; (3) neck surgery; and (4) idiopathic. [In view of the association of arm pain and the clinical findings in our patient, however, the best diagnosis was Parsonage-Turner syndrome.]

Despite the severity and extent of the lesion, overall prognosis is excellent. Recovery usually begins within a month or two but may not be complete for up to two years.

The first reported association of hemidiaphragmatic paralysis with brachial plexitis appeared in the French literature in 1950.⁵ Since then, several case reports have been published.⁶ In all cases, paralysis has been ipsilateral to the plexus involvement. The mode of onset is difficult to ascertain as it may exist without significant impairment of respiration. In symptomatic patients, onset was abrupt, like the pain of brachial plexopathy. In some patients, diaphragmatic paralysis, unlike the reversible shoulder and extremity weakness, may be permanent. The incidence of

diaphragmatic dysfunction in Parsonage-Turner syndrome is not known.

In a small number of cases, awareness of this neurologic entity may afford an explanation to an otherwise mysterious paralysis of the hemidiaphragm.

References

1. Rennels GD, Ochoa J. Neuralgic amyotrophy manifesting as anterior interosseous nerve palsy. *Muscle Nerve* 1980; **3**: 160-164.
2. Spillane JD. Localised neuritis of the shoulder girdle. Report of 46 cases in MEF. *Lancet* 1943; **2**: 532-535.
3. Parsonage MJ, Turner JW. Neuralgic amyotrophy; the shoulder-girdle syndrome. *Lancet* 1948; **1**: 973-978.
4. Tsairis P, Dyck PJ, Mulder DW. Natural history of brachial plexus neuropathy. Report on 99 patients. *Arch Neurol* 1972; **27**: 109-117.
5. Alajouanine T, Blatrix C. Paralyse amyotrophique des muscles periscapulaires, bilatérale et asymétrique, a début brusque et douloureux. *Rev Neurol* 1950; **82**: 280-281.
6. Cape CA, Fincham RW. Paralytic brachial neuritis with diaphragmatic paralysis; contralateral recurrence. *Neurology* 1965; **15**: 191-193.